

## Management of DME

---

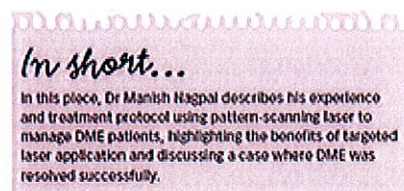
### Benefits of pattern scanning laser treatment and photo-thermal stimulating management software

Apr 1, 2014

By: [Dr Manish Nagpal](#)

Ophthalmology Times Europe

The management of diabetic macular oedema (DME) has undergone a dramatic shift since the advent of ocular coherence tomography (OCT). The findings on the OCT help my colleagues and I determine the best course of action for each patient.



OCT differentiates cases that may require a surgical treatment from those that may require anti-VEGF or laser treatment or a combination of both. Most surgeons use some combination of these two modalities in their treatment protocol for DME.

#### Practice benefits of pattern laser delivery

In 2007, I acquired the PASCAL (Topcon Medical Laser Systems, Capelle a/d IJssel, The Netherlands) technology that not only provided pattern delivery but also reduced laser exposure time with short pulse durations down to 10 ms.

The short pulse durations result in less diffusion of heat to surrounding areas, localized homogeneous burns and less pain during the procedure. Patients and surgeons appreciate a laser procedure that is made less tedious by both shortening the procedure time and decreasing patients' discomfort without sacrificing efficacy.

Back in 2010, my colleagues and I compared the efficacy, collateral damage and convenience of using a single-spot 532-nm solid-state green laser at 100 ms versus a multispot 532-nm pattern-scanning laser with algorithm-based software at 20 ms.<sup>1</sup>

Sixty patients with DME underwent panretinal photocoagulation, one eye with a single-shot 532-nm solid-state green laser and the other with a multispot 532-nm pattern-scanning laser. Grade 3 burns with a 200-µm spot size were placed with both imaging modalities. We analysed the fluence, pain using the visual analogue scale, time, laser spot spread with infrared images and retinal sensitivity.

The pattern scanning laser and 532-nm solid-state green laser required an average fluence of 40.33 vs 191 J/cm<sup>2</sup>, respectively. The average time of each procedure was 1.43 minutes with the pattern scanning laser and 4.53 minutes with single-shot 532-nm solid-state green laser. The average visual analog scale reading was 4.6 for the 532-nm solid-state green laser and 0.33 for the pattern-scanning laser. Retinal angiography images showed the spot spread as 430 with the 532-nm solid-state green laser and 310 with the pattern-scanning laser at 3 months postoperatively.

Finally, eyes treated with the pattern scanning laser showed higher average retinal sensitivity in the central 15° and 15° to 30° zones than the eyes treated with the single-spot 532-nm solid-state green laser.

We, therefore, concluded that the pattern scanning laser with algorithm-based software showed less collateral damage and similar regression of retinopathy. It was also less time consuming and less painful for the patient.<sup>1</sup>

In 2012, the company developed Endpoint Management as a method of precisely controlling laser energy as it relates to the titration level, which is more beneficial for treating patients with lower energies than conventional photocoagulation.

Using this software, the clinician can titrate the laser power to a barely visible burn. Then they are able to select a percentage of the required titration energy to deliver to the treatment locations. It can be used for 532 nm (green) and 577 nm (yellow) laser wavelengths.

#### **DME treatment protocol**

When my colleagues and I see a patient with DME and suspected maculopathy we clinically examine the patient with a series of steps. First, the patient is tested for visual acuity and IOP, and a detailed ophthalmic assessment is performed. A slit-lamp based examination of the macula is performed to assess the extent of oedema. Lastly, we perform an OCT scan to confirm the diagnosis.

OCT helps us determine the thickness of the macula. It also confirms if there is a cystoid oedema, subfoveal fluid, or traction due to hyaloidal pull and membrane formations. If the OCT shows that the patient has significant oedema, we administer anti-VEGF injections to reduce the oedema for 1 month followed by pattern scanning laser treatment with Endpoint Management. If the oedema is minimal, a combination of laser treatment and anti-VEGF injections is effective. For an example of our procedure, please see Sidebar 1 for a case study.

#### **Laser use with minimal damage**

Endpoint Management has allowed my colleagues and I to use a multispot laser with all its inherent advantages and then use a sub-threshold laser to treat with the least amount of collateral damage. Moreover, unlike micropulse, Endpoint Management allows the surgeon to visually see where he or she has placed burns and plan the treatment without any overlaps. Therefore, this software allows a visual cue for the surgeon while having the benefits of a micropulse laser.

#### **Reference**

1. M. Nagpal, S. Marlecha and K. Nagpal, *Retina*, 2010;30(3):452–458.